BUSH ADVANCED
VETERINARY IMAGING

QUARTERLY CASE REPORT

FUNGAL INFECTIONS -

Using CT as a Diagnostic Tool

Signalment, History, and Physical Exam Findings

Lottie, a 3 year old, intact, male German Shorthair Pointer Mix from the US Customs Authority was shipped from Texas to Virginia three months ago. One month later the staff members observed that he began losing weight, his appetite had decreased by approximately 40% and he had developed a cough. He was also noted to be febrile (103-104 F). Lab work was done showing a leukocytosis with a neutrophilia and monocytosis. A hyperglobulinemia was also noted that was later determined to be polyclonal. He was placed on Amoxicillin and Metronidazole which did not change his appetite or alter his temperature. Lottie was then seen by an internal medicine specialist and had an abdominal ultrasound performed which showed moderate mesenteric lymphadenopathy. Chest radiographs and a thoracic ultrasound were also performed at this time and revealed a 5.7 X 5.0 cm bilobed soft tissue structure thought to be either a hilar lymph node or less likely a neoplastic mass. Fungal antigen titers (Histoplasmosis, Blastomycosis and Coccidiomycosis) were also performed and were all negative.

Lesion Localization and Differential Diagnosis

The mass effect in Lottie's chest was felt to be a key clinical finding as to the origin of his fever and inappetance. Because of Lotties travel history, fungal disease causing lymphadenopathy was still suspected, despite the negative fungal antigen titers. Additional rule outs included a primary lung tumor, foreign body reaction (migrating plant awn), metastatic disease.

THORACIC CT

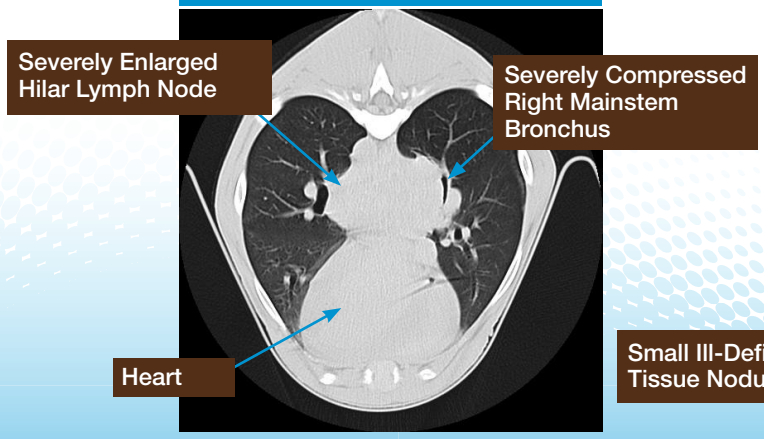

THORACIC CT

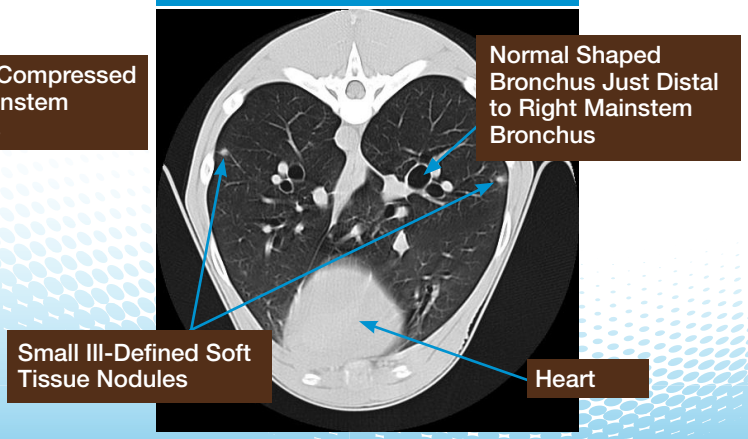

UPDATE

Both of our imaging sites have been a huge success in the Northern Virginia area, thanks to many of you that are reading this. Due to the success we have had in this region, we have elected to expand our services to Richmond, VA in the fall of this year. For those of you you who reside and practice in the Richmond area, please keep an eye out for our announcements regarding the exact date and location of our new facility.

LEARN ABOUT VETERINARY MRI

Technology is changing the way we practice medicine but it can be very difficult to keep up with all of the advances. Let us help. We are available to meet with you and your staff to discuss the value of MRI and CT imaging in the practice of veterinary medicine. Call us today to arrange a meeting. We'd be happy to bring in breakfast, lunch, or dinner.

A special thank you to Dr. Megan Keyes, the medical director of the US Customs facility in Front Royal, VA, for being such a wonderful advocate for these service dogs. In addition a special thank you to Dr. Nichole Birnbaum of the Veterinary Internal Medicine Practice of Northern VA for recommending a CT study for Lottie.

CT Findings

A pre and post contrast thoracic CT was performed using 3 mm contiguous slices through the entire thorax There is a large, contrast enhancing mass noted between the main stem bronchi in the perihilar region most consistent with lymphadenopathy. This mass measures about 6 x 4.7 cm. It is causing lateral displacement and compression of the main stem bronchi. There are also several, small, ill-defined 5-6 mm in diameter soft tissue nodules noted within the pulmonary parenchyma.

Radiographic Conclusions

Large, perihilar mass most consistent with lymphadenopathy. Multiple small, ill-defined soft tissue pulmonary nodules. Given the clinical history and findings noted, coccidiomycosis would be a primary consideration for the cause of the changes and signs. Lymphoma seems unlikely given the pulmonary nodules that are present. Metastatic neoplasia of other origin also seems unlikely given the profound hilar lymphadenopathy present. For more information on coccidiomycosis, go to www.bushvetimaging.com/coccidiomycosis.html.

Follow up

Based on the results of the CT, a decision was made to treat Lottie with fluconazole and also to repeat his fungal titers, this time performing an antibody test. Within a few days of initiating therapy, Lottie began eating better, became afebrile and has now returned to performing his usual antics (like throwing his Kong toy up in the air and then chasing after it)! The antibody titers were received ten days after the CT and confirmed that Lottie had been exposed to Coccidiomycosis; his IgG titer was positive at 1:64. He has been on continuous antifungal therapy for several months and his IgG titer has now decreased to 1:4. Clinically he has made a complete recovery and should be able to go back to service soon.

Discussion

Many of the Lottie's clinical signs and laboratory findings can be attributed to a chronic fungal infection. These would include: General malaise, coughing, fever, inappetance, weight loss, exercise intolerance, polyclonal gammopathy, mild anemia, and monocytosis. The cough is felt to be primarily caused by the marked hilar lymphadenopathy causing severe compression of the mainstem bronchi, in particular, the right mainstem bronchus. While chronic infection alone could cause exercise intolerance, it is possible that the compression of the right mainstem bronchus is also a cause of the exercise intolerance as this would restrict airflow to the right lung fields.

This is a very interesting case presentation in our region and reinforces the reason we always ask, "Has your pet traveled outside of Virginia?"

info@bushvetimaging.com
www.bushvetimaging.com